

# Squamous Papilloma Causing Airway Obstruction During Conscious Sedation

Paul Brady, BDS, MFDS, FFDRCSI(OS), MSc Con Sed, Christine McCreary, MD, FDS(OM), FFDRCSI, Ken D. O'Halloran, BSc, PhD, and Catherine Gallagher, MB, FDSRCS, FFDRCSI(OS)

University College Cork, Ireland

Monitoring for respiratory depression is essential during conscious sedation. We report a case of a squamous papilloma as an unusual cause of intermittent partial airway obstruction in a 43-year-old man undergoing intravenous conscious sedation with midazolam. The Integrated Pulmonary Index (IPI) is an algorithm included in some commercially available monitors that constitutes a representation of 4 parameters: end-tidal carbon dioxide, respiratory rate, oxygen saturation, and pulse rate. We discuss the potential of the IPI as a monitoring tool during sedation.

**Key Words:** Conscious sedation; Airway; Capnography.

The sedationist-operator model is popular in minor oral surgery and is commonly used in North America and parts of Europe. This report describes a case of respiratory obstruction in a patient during sedation in an outpatient setting. In this setting, minimal to moderate sedation is the target level on the sedation continuum, based on patient response. Single-drug intravenous conscious (moderate) sedation was achieved by titrating midazolam to an end point with signs including slurring and lowering of speech, a relaxed demeanor, a delayed response to commands, and drooping of the upper eyelids.

Clinical monitoring and pulse oximetry are mandatory in the United Kingdom and Ireland.<sup>1</sup> Oxygen saturation ( $\text{SpO}_2$ )  $\leq 94\%$  is regarded as an early warning sign of respiratory compromise in this setting. Supplemental oxygen is not routinely administered during our conscious sedation technique. The use of midazolam as a single drug for conscious sedation has been analyzed by several studies that demonstrated an incidence of differing levels of hypoxemia between 17 and 33%.<sup>2-4</sup> Currently, in the United Kingdom and Ireland, capnography monitoring is not required for American Society

of Anesthesiology physical status 1 and 2 patients undergoing conscious sedation for dental procedures.<sup>1</sup> However, we used the Capnostream 20 vital signs monitor (Oridion, Jerusalem, Israel), which uses a Smart Capnography algorithm for the calculation of the Integrated Pulmonary Index (IPI). We discuss the potential of the IPI as a monitoring tool in this setting.

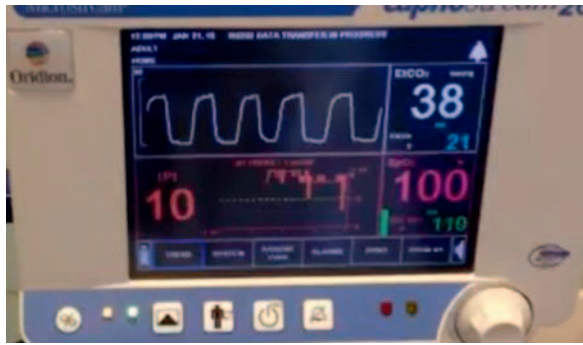## CASE REPORT

A 43-year-old man (height 170 cm, weight 75 kg) was referred to the Cork University Dental School and Hospital for removal of mandibular impacted third molar teeth. He had a body mass index of 26 and was considered American Society of Anesthesiology physical status I. He admitted to smoking 14 cigarettes per day for 10 years. His past medical history was otherwise clear. After we had applied monitors, registered baseline vital signs, and obtained intravenous access, a total of 8 mg of midazolam was titrated at a rate of 1 mg/min to an end point where the patient appeared drowsy but verbal contact was maintained. Local anesthetic was administered. Standard monitoring included observation of clinical signs, continual blood pressure measurements, and pulse oximetry. Additional monitoring with microstream capnography via an oral-nasal sampling cannula was undertaken as part of a research study. End-tidal carbon dioxide ( $\text{EtCO}_2$ ), respiratory rate

Received December 15, 2016; accepted for publication January 4, 2017.

Address correspondence to Dr Paul Brady, Cork University Dental School and Hospital, Wilton, Cork, Ireland T12 E8YV; paul.brady@ucc.ie.

Anesth Prog 64:168-170 2017 | DOI 10.2344/anpr-64-03-07  
© 2017 by the American Dental Society of Anesthesiology



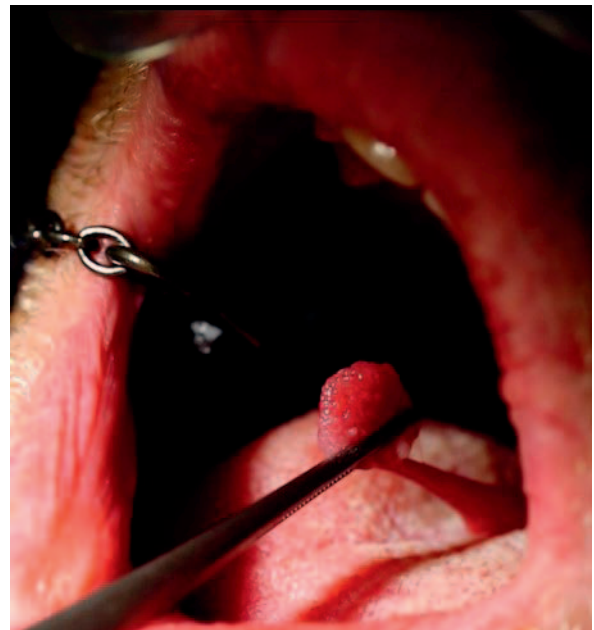
**Figure 1.** Example of monitor with capnography displayed.

(RR), SpO<sub>2</sub>, and pulse rate (PR) readings were continuously recorded (Figure 1).

This patient was in the control arm of a clinical trial and information regarding capnography was not directly available to the clinicians during the procedure (Figure 2). Ethical approval for the trial was obtained from the Cork Research Ethics Committee.

After induction, the patient experienced repeated oxygen desaturations in the range of 87–94%, which were detected by a finger pulse oximetry probe. He responded on each occasion to verbal calls for breaths, which corrected the hypoxemia. However, the corrections were transient and he continued to repeatedly experience hypoxemia.

On visual inspection of the oropharynx, a lesion was discovered attached to the uvula (Figure 3). The pedunculated nature of the lesion allowed it to extend and partially obstruct the airway, analogous to a bungee cord. The lesion was immediately excised without local anesthesia as it was felt to be an urgent condition requiring attention. Histopathology reported the lesion (0.8 × 0.9 × 0.5 cm) as a benign squamous papilloma. He went on to have the impacted mandibular teeth removed



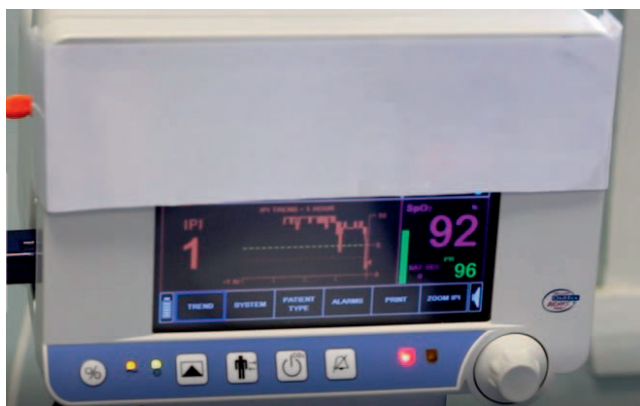**Figure 3.** Pedunculated lesion attached to the uvula.

at this visit and he had an uneventful postoperative recovery.

As we had recorded electronic data, we were able to perform a post hoc analysis of the monitoring parameters. In particular, we were able to look at the capnography parameters and the IPI.

Sample electronic recordings taken during the sedation are shown in the Table. Continuous data from the monitor were acquired on a computer, employing specific oximetry software (Profox Associates Inc USA, Escondido, Calif).

We can see from the Table that baseline parameters were within normal limits. When a desaturation occurred (circa 15.14.28), the EtCO<sub>2</sub> was very low and the patient was apneic. Following stimulation to take breaths, the patient’s RR and SpO<sub>2</sub> returned to normal limits within 30 seconds. There was a sharp rise in



**Figure 2.** Vital signs monitor with capnography information obscured.

**Monitoring Parameters\***

	Time	EtCO <sub>2</sub> (mm Hg)	RR (beats/min)	SpO <sub>2</sub> (%)
Normal		35–45	12–20	≥95
Baseline	14.50.30	38	20	97
1 mg	14.51.00	41	18	98
6 mg	14.56.00	36	19	95
Desaturation	15.14.28	5	0	92
Stimulation	15.15.00	27	18	97
	15.15.14	26	13	99

\* EtCO<sub>2</sub> indicates end-tidal carbon dioxide; RR, respiratory rate; and SpO<sub>2</sub>, oxygen saturation.

EtCO<sub>2</sub>, but it did not return to normal limits within this time frame.

The IPI is displayed on the lower left side of the monitor (Figure 1). The IPI is an algorithm that constitutes a representation of 4 parameters: EtCO<sub>2</sub>, RR, SpO<sub>2</sub>, and PR. The IPI is presented as an integer ranging from 1 to 10, where 10 is healthy and 1 requires immediate intervention.<sup>5</sup> The IPI has been validated for adults and for children older than 1 year.<sup>6,7</sup>

## DISCUSSION

This case report highlights the importance of monitoring during conscious sedation. When a patient experiences hypoxemia, the possibility of a soft tissue lesion causing obstruction in the airway should be considered. This patient did not report any prior history of sleep-related respiratory obstruction, snoring, or sleep apnea. Snoring was not a feature of the obstruction during the sedation procedure. Our presedation assessment for this patient did not include a physical examination of the airway specifically. In anesthesia, Mallampati scoring is used as a method of classifying the airway by visual inspection.<sup>8</sup> We have recently introduced this airway evaluation modality as part of our presedation assessment.

In this setting, supplemental oxygen is not routinely administered, as supplemental oxygen is likely to blunt the sensitivity of pulse oximetry as an indirect monitor of ventilation. If supplemental oxygen had been used in this case, it is likely that SpO<sub>2</sub> would have remained within normal limits ( $\geq 95\%$ ). Had we been able to observe the capnography waveform, it is likely that we would have detected the obstruction earlier. However, pulse oximetry as a surrogate monitor of ventilation did indicate that there was a respiratory issue. In this setting with a natural airway, a low EtCO<sub>2</sub> is to be expected with respiratory obstruction. Although we did not consider analysis of the IPI in the clinical trial, on retrospective investigation we determined that the IPI index effectively illustrates and quantifies respiratory disturbance despite satisfactory pulse oximetry (see Figure 2 with IPI of 1). For nonanesthesiologist personnel providing sedation, looking at different parameters such as SpO<sub>2</sub>, PR, RR, and EtCO<sub>2</sub> may be confusing and lead to an underestimation of the clinical situation. Additionally, in the sedationist-operator model, the monitors are not continuously visualized, although pulse oximetry tones are continuously audible. In such a situation, the IPI, or even capnography alone, appears to provide a better indicator, in real time, of overall ventilatory status. These ventilation parameters would be helpful in determining the need for additional

clinical assessment or intervention, especially if set at an appropriate level to alarm.

## CONCLUSION

We present a case of airway obstruction and hypoxemia under moderate sedation secondary to an airway soft tissue lesion. Use of capnography, particularly with an algorithm-derived measure of ventilatory function, appears to be of value in detecting respiratory compromise.

## ACKNOWLEDGMENTS

We thank the Health Research Board (HPF/2013/458) for partially funding the study, along with Covidien for providing the monitor on loan.

## REFERENCES

1. Inter-Collegiate Advisory Committee for Sedation in Dentistry. *Standards for Conscious Sedation in the Provision of Dental Care*. London, England: The Dental Faculties of the Royal Colleges of Surgeons and the Royal College of Anaesthetists; 2015.
2. Allgayer H, Pohl C, Kruis W. Arterial oxygen desaturation during endoscopic ultrasonography combined with gastroscopy: a safety evaluation in out-patients. *Endoscopy*. 1999;31:447–451.
3. Wang C, Ling L, Cardoso M, Wong A, Wong N. Hypoxia during upper gastrointestinal endoscopy with and without sedation and the effect of pre-oxygenation on oxygen saturation. *Anaesthesia*. 2000;55:654–658.
4. Brady P, Wilson K, Meeke R, Girdler N, McCreary C. Capnometry monitoring during intravenous sedation with midazolam for oral surgery. *Oral Surg*. 2015;9:94–101.
5. Taft A, Ronen M, Epps C, Waugh J, Wales R, eds. A novel Integrated Pulmonary Index (IPI) quantifies heart rate, Etco<sub>2</sub>, respiratory rate and SpO<sub>2</sub>. *Anesthesiology*. 2008;109:A1682.
6. Berkenstadt H, Ben-Menachem E, Herman A, Dach R. An evaluation of the Integrated Pulmonary Index (IPI) for the detection of respiratory events in sedated patients undergoing colonoscopy. *J Clin Monit Comput*. 2012;26:177–181.
7. Sabbatani P, Mantovan R. Electrical cardioversion of atrial fibrillation: evaluation of sedation safety with midazolam by means of EtCO<sub>2</sub> and IPI algorithm analysis. *Int J Cardiol*. 2013;169:430–432.
8. Mallampati SR, Gatt SP, Gugino LD, et al. A clinical sign to predict difficult tracheal intubation; a prospective study. *Can Anaesth Soc J*. 1985;32:429–434.